

**Colorado Dermatology Center Newsletter**  
*Case Studies - Anterior Thinning of Scalp Hair*

Dear Colleague:

Next in our series of case studies shall be clinical examples of the creation of fine, natural HAIRLINES. A zone of single hairs, consisting of 100–200 follicles, is implanted at the desired location. This is closely followed by a zone of 100–180 2–hair follicular units immediately behind the single hairs. The anterior hairline zone is then covered with 3–hair follicular units. These follicular units (intact donor groups) of 1, 2, or 3 hairs are dissected under magnification and are implanted using magnifiers into needle slits with ultrafine jeweler's forceps.

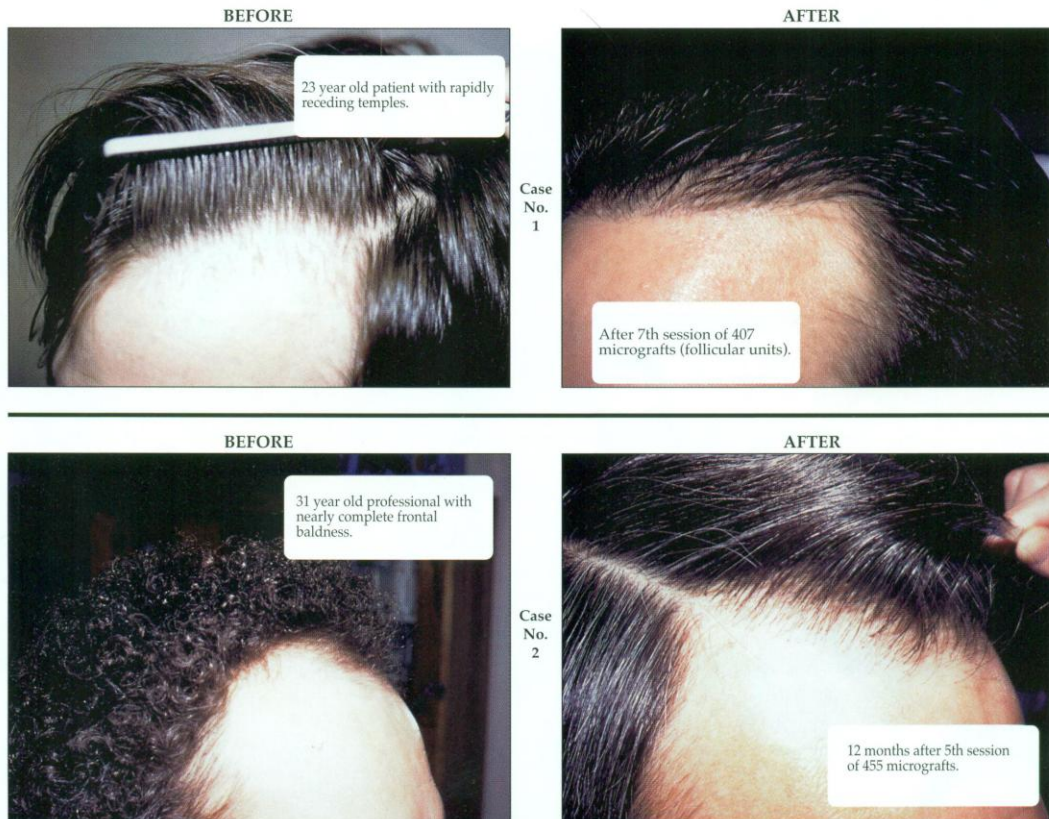
If you viewed only the "after" photos in these three cases, could you tell that they had received transplants? If not, then you can appreciate the attention to detail necessary in creation of beautiful hairlines in hair restoration surgery: 300 or more follicular units have been placed into a frontal zone only 1 cm wide!

We would appreciate the referral of any patients desiring advice concerning the medical or surgical options available for hair loss. Your patients may schedule a free hair transplant consultation by calling (303) 744–1202, or may view photographs online at [www.coloderm.com](http://www.coloderm.com), or [www.HairTransplantColorado.com](http://www.HairTransplantColorado.com).

Sincerely,

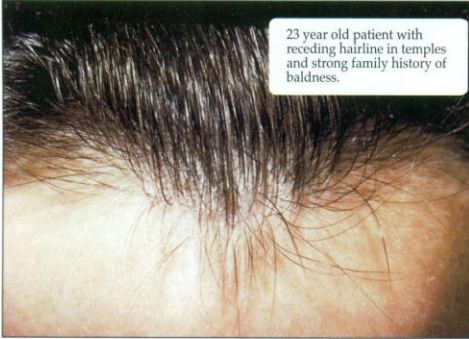


James M. Swinehart, M.D.



## HAIRLINE REFINEMENT WITH FOLLICULAR UNIT GRAFTING

BEFORE



AFTER

