

Colorado Dermatology Center Newsletter
Case Studies - Creation of Fine, Natural Hairlines

Dear Colleague:

We have all seen unfortunate patients with older "bristle brush" hairlines from larger plugs. However, you may also have heard about the newer "follicular unit grafting" techniques utilizing micrografts produced under a stereotactic dissecting microscope. Since commencing this procedure several years ago, our level of patient satisfaction is the highest that it has been in the 29 years that I have performed hair replacement surgery.

With microscopic dissection, our surgical staff is able to **precisely** create micrografts with 1, 2, 3, or 4 hairs. We then create a "density gradient" with single hairs only for the hairline, a zone of 2-hair micrografts in the front of the scalp, and 3-4 hair micrografts for the crown. As a result, extremely natural outcomes are now possible.

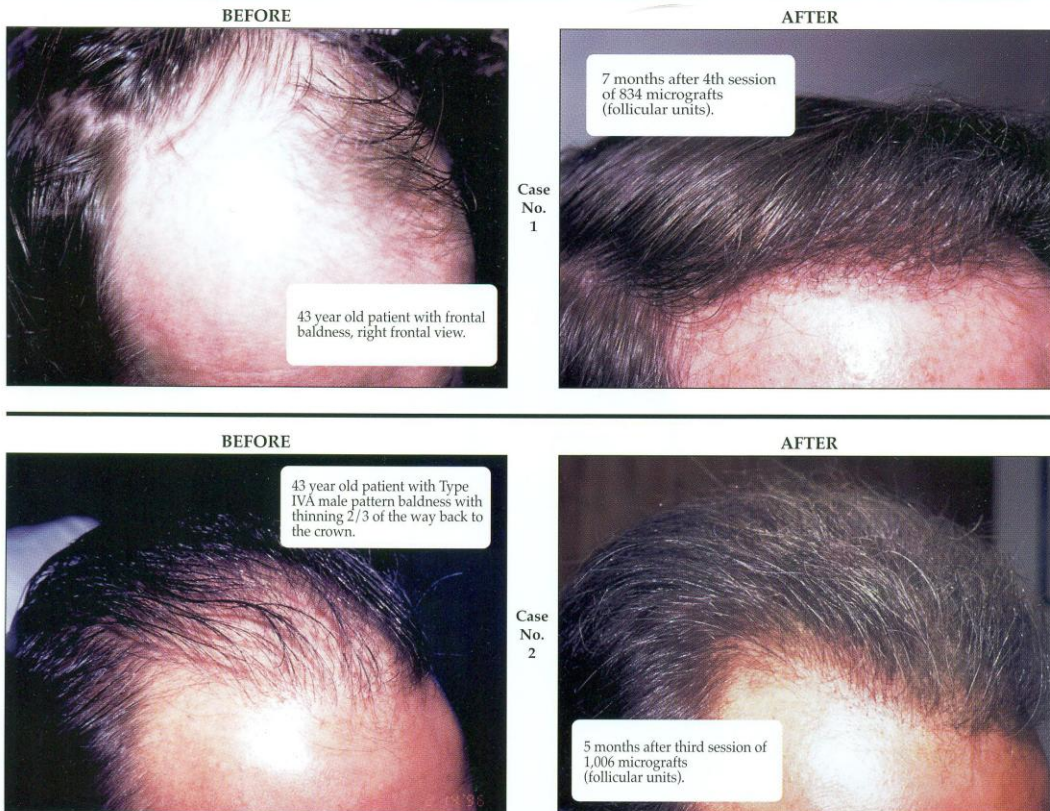
These follicular units can be placed into the frontal forelock and into lateral and posterior zones of thinning to counteract future hair loss and to prevent the future appearance of baldness. Very fine cloned hairs can be placed at the hairline for a feathered look.

I would like to share with you the following case studies illustrating how natural hair replacement can look in patients with ANTERIOR THINNING. Your patients may view many more photographs at www.coloderm.com, or www.HairTransplantColorado.com, or may call (303) 744-1202 to schedule a free consultation.

Sincerely,

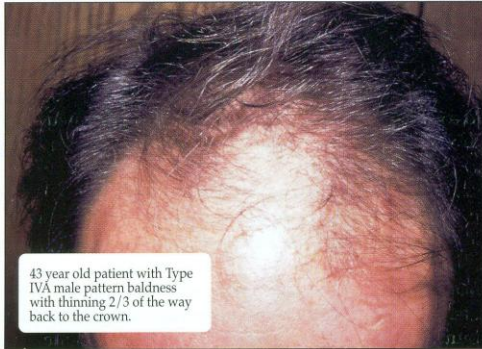


James M. Swinehart, M.D.



FOLLICULAR UNIT GRAFTING FOR MALE PATTERN BALDNESS

BEFORE



AFTER

