

**Colorado Dermatology Center**



Dear Hair Care Professional:

Your patients with DIFFUSE THINNING of the scalp hair, due to male pattern baldness or female pattern alopecia, may have already tried Rogaine®. Men may see some benefit on the posterior scalp with Propecia® – but must take this for the rest of their lives in order to maintain the growth.

Now, with extensive micrografting utilizing microscopic follicular units containing 1-4 hairs each, we can prevent the visual appearance of baldness. The existing hairs are left undisturbed –but the tiny bundles of follicular bulbs are meticulously inserted under magnification into tiny needle holes in between the patient’s remaining scalp hairs. We can also recreate the “whorl” on the posterior crown, and graft into areas of anticipated future thinning at the edges of the balding scalp.

Micrografting is both an art and a science. Recently, the insertion of 1,720 micrografts took us 7 hours for the physician and four surgical assistants. We have performed over 1,500 grafts in a single session in a female with familial thinning, and over 1,800 micrografts in several men. However, the fruits of this labor are well worth the effort.

Enclosed please find case studies of my patients with diffuse thinning of the scalp hair. Your patients may view more photos as [www.coloderm.com](http://www.coloderm.com).

Thank you for allowing me to share this with you.

Sincerely,

A handwritten signature in black ink that reads "Swinehart M.D." in a cursive style.

James M. Swinehart, M.D., President  
Colorado Dermatology Center

JMS/sl

**JAMES M. SWINEHART M.D.**

DIPLOMATE, AMERICAN BOARD OF DERMATOLOGY

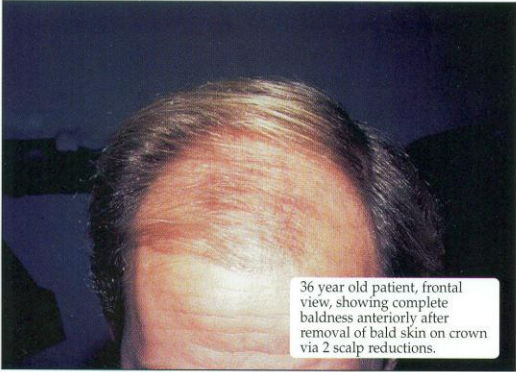
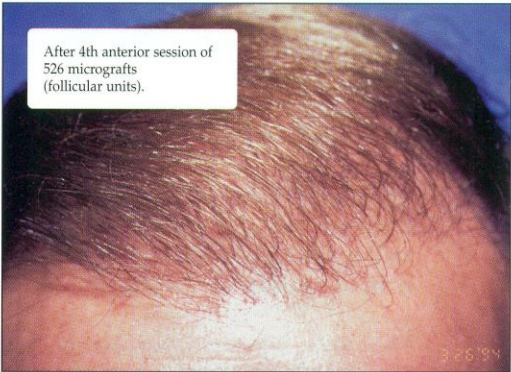
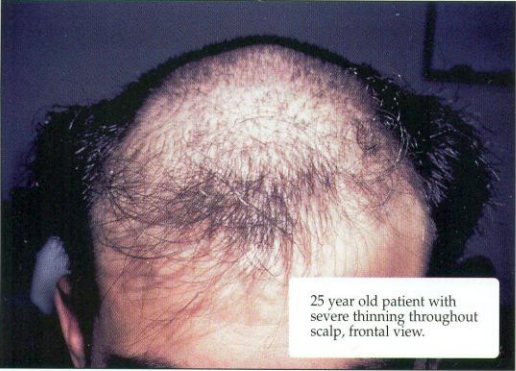
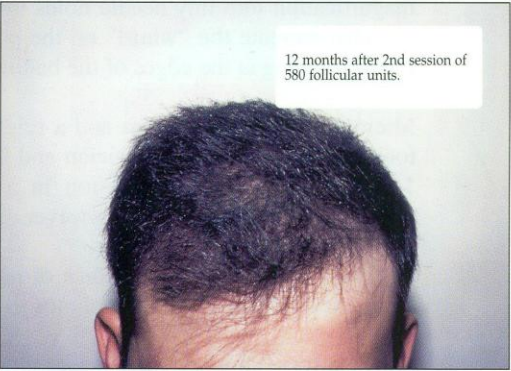
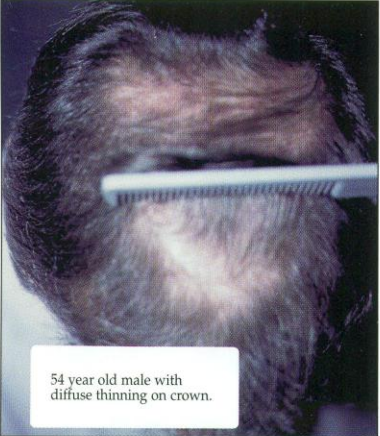
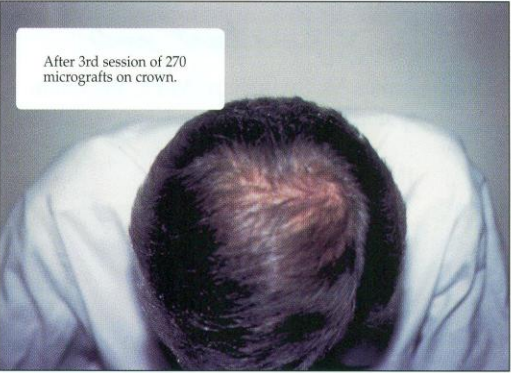
HARVARD PARK MEDICAL PLAZA • 950 EAST HARVARD AVENUE • SUITE 630 • DENVER, COLORADO 80210 (303) 744-1202

HAIR LOSS CLINIC  
OF COLORADO  
(303) 744-1202



JAMES M. SWINEHART, M.D.  
950 E. HARVARD AVENUE, SUITE 630  
DENVER, CO 80210 USA  
FAX 303-744-0418  
www.coloderm.com

COLORADO DERMATOLOGY CENTER

BEFORE	AFTER	
 <p data-bbox="540 768 740 848">36 year old patient, frontal view, showing complete baldness anteriorly after removal of bald skin on crown via 2 scalp reductions.</p>	 <p data-bbox="898 531 1097 590">After 4th anterior session of 526 micrografts (follicular units).</p>	<p>CASE NO. 1</p>
 <p data-bbox="540 1205 740 1264">25 year old patient with severe thinning throughout scalp, frontal view.</p>	 <p data-bbox="1146 961 1346 1020">12 months after 2nd session of 580 follicular units.</p>	
 <p data-bbox="354 1709 526 1747">54 year old male with diffuse thinning on crown.</p>	 <p data-bbox="898 1423 1065 1461">After 3rd session of 270 micrografts on crown.</p>	<p>CASE NO. 3</p>